



Spitfire's STORY

SPECIES	Feline
BREED	Domestic Shorthair
AGE	10 months
SEX	Female Spayed
INJURY	Degloving
TREATMENT	3 total applications of ReCruit™ Topical
RESULTS	Complete healing of the wound and full use of limb 61 days after initial application

ReCruit™ Topical

POWDERED EXTRACELLULAR MATRIX

Clinical Evaluation | Case Study

The product was applied to what type of wound?

Hit-by-car traumatic degloving injury to the plantar metatarsal and phalangeal area of the right hind limb. Initial wound appearance was dirty with necrotic tissue present.

How was the wound prepared?

It was cleaned, in which gross debris was removed and the necrotic tissue was surgically debrided.

How was the product applied?

It was sprinkled onto the wound, applying a full coat of product across the wound bed. A full bottle (1 gram) was applied at the initial application. After applying the product, a non-adherent pad and bandage was applied to protect the wound.

Were bandage changes needed?

Yes - at minimum, a weekly bandage change was needed for 6 weeks.

How many applications of the product were needed?

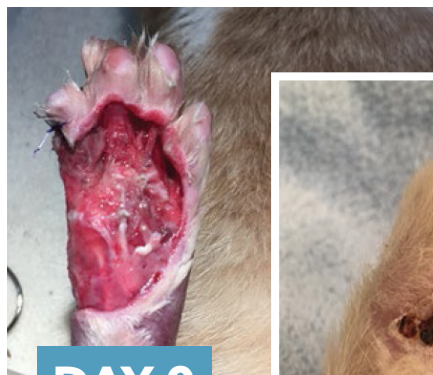3

Did the patient experience any complications due to the product?

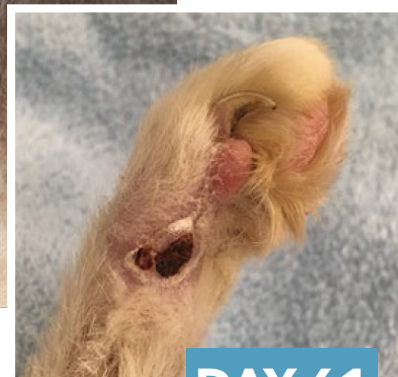
No

How did the product perform?

Very well - it enhanced healing time, improved patient comfort, and prevented the patient from having a limb amputation surgery.



DAY 0



DAY 61



Learn more about how ReCruit™ Topical is helping animals at cookanimalhealth.com/recruit